

Hand Surface Landmarks and Measurements in the Treatment of Trigger Thumb

Ronak M. Patel, MD, Brian J. Chilelli, MD, Andre D. Ivy, MD, David M. Kalainov, MD

Purpose To determine hand surface landmarks and measurements that may be useful in localizing the A1 pulley and digital neurovascular structures in the treatment of trigger thumb.

Methods We highlighted 4 surface landmarks in 20 adult cadaveric hands: the radial border of the index finger, the ulnar border of the thumb, the thumb interphalangeal joint flexion creases, and the thumb metacarpophalangeal joint creases. We injected the radial arteries with red latex and dissected the thumbs.

Results The proximal margin of the A1 pulley was located an average of 0.3 mm proximal (range, 3.2 mm proximal to 2.3 mm distal) to the most proximal metacarpophalangeal joint flexion crease. The ratio of measurements from the thumb tip to the midpoint of the interphalangeal joint flexion creases and from this point to the proximal margin of the A1 pulley averaged 1.1:1. The radial digital nerve crossed obliquely over the flexor pollicis longus tendon and approached the proximal margin of the A1 pulley at a mean distance of 2.7 mm (range, 0–12.9 mm). The ulnar digital nerve was located deep to intersecting lines drawn along the radial border of the index finger and the ulnar border of the thumb and coursed parallel to the A1 pulley at a mean distance of 5.4 mm (range, 0–11.1 mm). At the level of the A1 pulley, the digital arteries were positioned dorsal to the digital nerves, and both nerves were located 1.0 to 4.2 mm from the skin surface.

Conclusions The findings from our study clarify hand surface landmarks in localizing the thumb A1 pulley and digital neurovascular structures.

Clinical relevance Awareness of topographical landmarks in localizing the A1 pulley and digital neurovascular structures and the relationships between the digital neurovascular structures and the A1 pulley may improve the safety and efficacy of trigger thumb treatment. (*J Hand Surg* 2013;38A:1166–1171. Copyright © 2013 by the American Society for Surgery of the Hand. All rights reserved.)

Key words Trigger thumb, stenosing tenosynovitis, tendon sheath, A1 pulley.

SUCCESSFUL TREATMENT OF trigger thumb may involve a corticosteroid injection into the tendon sheath or surgery to release the A1 pulley by open or percutaneous techniques.^{1,2} Both injection and surgical intervention necessitate familiarity with the lo-

cation and structural anatomy of the tendon sheath and neurovascular structures.

The radial border of the index finger, the ulnar border of the thumb, and the flexion creases of the thumb are easily identified topographical landmarks in the

From the Department of Orthopaedic Surgery and the Northwestern Center for Surgery of the Hand, Northwestern University Feinberg School of Medicine, Chicago, IL.

Received for publication November 7, 2012; accepted in revised form February 8, 2013.

No benefits in any form have been received or will be received related directly or indirectly to the subject of this article.

Corresponding author: David M. Kalainov, MD, Northwestern Center for Surgery of the Hand, Department of Orthopaedic Surgery, Northwestern University Feinberg School of Medicine, 737 N Michigan Ave # 700, Chicago, IL 60611; e-mail: dkalainov@comcast.net.

0363-5023/13/38A06-0017\$36.00/0
<http://dx.doi.org/10.1016/j.jhsa.2013.02.028>

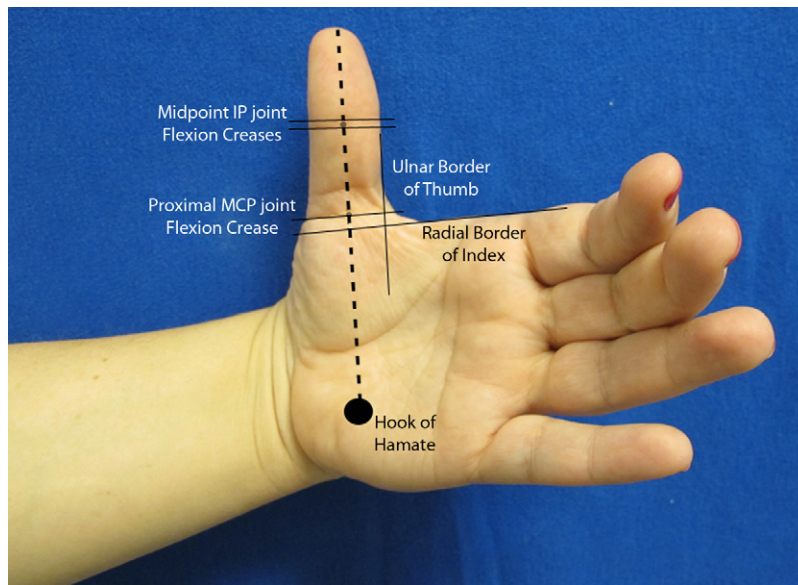


FIGURE 1: Hand surface markings with the thumb in extension so that the open angle between the thumb and the neutrally aligned index finger approximated 90°. The dotted line indicates the planned incision from the thumb pulp to the hook of hamate.

uninjured hand. Previous anatomical and clinical studies have evaluated the thumb metacarpophalangeal (MCP) joint flexion creases and the dorsal prominence of the first metacarpal head as surface landmarks for localizing the A1 pulley.^{3–6} Authors have reported variability in the number of skin flexion creases in the thumb, and the dorsal prominence of the first metacarpal head may be difficult to localize.⁴

We performed a cadaveric study to assess hand surface landmarks as potential reference points in localizing the thumb A1 pulley. In addition, we measured relevant portions of the thumb flexor tendon sheath and determined the positions of the volar digital neurovascular structures in relationship to the surface landmarks and A1 pulley.

MATERIALS AND METHODS

We obtained 20 fresh-frozen hand specimens from 17 cadavers (11 men and 6 women) for this study, sectioned at the midforearm level. The mean age of the specimens was 75 years (range, 50–92 y). Normal thumb length was confirmed in each specimen by a continuous thenar arc, defined by an unbroken curvilinear line between the thumb interphalangeal (IP) joint flexion creases and the thenar crease of the palm with the thumb adducted against the index finger.⁷ There were 1 to 3 IP joint flexion creases, spanning a distance of 2.4 to 8.6 mm, and 1 to 2 more widely spaced MCP joint flexion creases, spanning a distance of 5.4 to 11.1 mm. All thumb joints were supple and without clinical evidence of instability. Fluoroscopic images revealed

underlying degenerative arthritis in the basal joints in 5 specimens.

We injected the radial artery of each specimen proximal to the wrist flexion crease with red latex (Columbus Chemical Industries, Inc., Columbus, WI) and allowed the liquid to harden.⁸ We amputated the pulp of the index finger to ensure penetrance of the substance into the tips of the digits. The hand was placed supine on a flat surface with the thumb and fingers extended, so that the open angle between the extended thumb and the neutrally aligned index finger approximated 90°. The wrist was then flexed and the forearm rotated to align the thumb vertically, with the palmar surface of the digit facing the investigator (Fig. 1).

We drew a straight line from the tip of the thumb pulp to the hook of hamate, bisecting the IP and MCP joint flexion creases. The flexor pollicis longus (FPL) tendon and tendon sheath normally project along a line that bisects the IP joint flexion creases and the hook of hamate with the thumb in radial abduction.⁹ We marked 4 surface landmarks with a pen: a line extending from the radial border of the proximal phalanx of the index finger to the volar surface of the thumb, a line extending along the ulnar border of the thumb, the midpoint of the thumb IP joint flexion creases, and the separate thumb MCP joint flexion creases.

We made a longitudinal skin incision from the tip of the thumb pulp to the hook of hamate along the depicted line. A small transverse skin incision was made across the thumb pulp, intersecting with the distal end of the longitudinal incision. We carefully raised skin

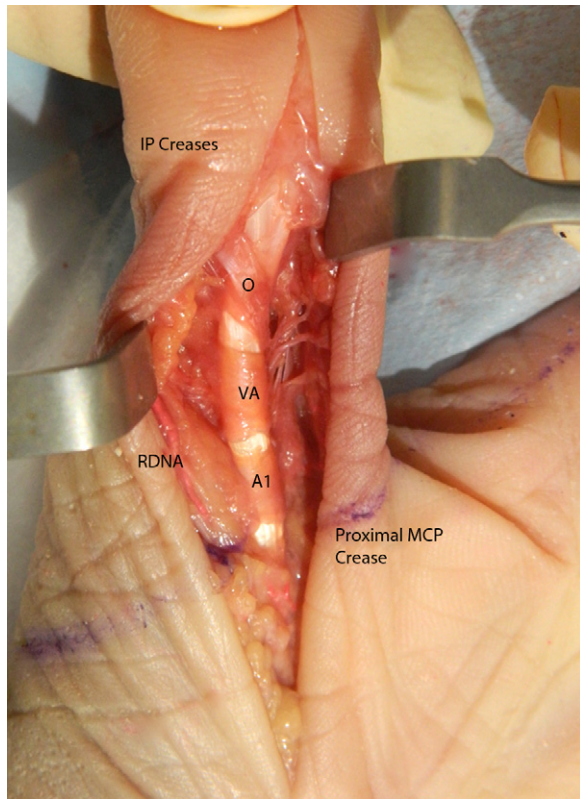


FIGURE 2: Exposure of the thumb flexor tendon sheath and neurovascular structures. RDNA, radial digital nerve and artery; A1, A1 pulley; VA, variable annular pulley; O, oblique pulley.

flaps medially and laterally with the aid of loupe magnification, and exposed the FPL tendon and tendon sheath (Fig. 2). We limited dissection and retraction of soft tissues as much as possible, to avoid distorting the anatomy.

We inserted needles through surface landmarks at right angles to the palmar plane of the thumb proximal phalanx and secured them upright in soft tissue. We obtained the following measurements using a digital caliper (Fig. 3): (1) the longitudinal and transverse widths of the A1 pulley, (2) the longitudinal widths of the variable annular and oblique pulleys, (3) the distance between the distal margin of the A1 pulley and the proximal margin of the variable annular pulley, (4) the distance between the midpoint of the IP joint flexion creases and the thumb tip, (5) the distance between the midpoint of the IP joint flexion creases and the proximal margin of the A1 pulley, (6) the distance between the proximal margin of the A1 pulley and a line extended proximally along the radial border of the index finger, and (7) the distance between the proximal margin of the A1 pulley and the proximal MCP joint flexion crease.

We performed further dissection to expose the radial and ulnar digital nerves and arteries to the thumb. We obtained the following additional measurements: (1) the diameters of the radial digital nerve (RDN), the radial digital artery (RDA), the ulnar digital nerve (UDN), and the ulnar digital artery (UDA) at level of the A1 pulley, (2) the distances of the RDN and the UDN from the skin surface at the level of the A1 pulley, (3) the distance between the proximal margin of the A1 pulley and the proximal crossing point of the RDN over the FPL tendon, (4) the distance between the proximal margin of the A1 pulley and the distal crossing point of the RDN over the FPL tendon, (5) the closest distances of the RDN and the RDA from the A1 pulley, (6) the closest distances of the UDN and the UDA from the A1 pulley, (7) the distance between the distal crossing of the RDN over the FPL tendon and the midpoint of the IP joint flexion creases, (8) the distance between the distal crossing point of the RDN over the FPL tendon and a line extended proximally along the radial border of the index finger, and (9) the distance of the UDN from intersecting lines drawn along the radial border of the index finger and the ulnar border of the thumb.

Statistics

We recorded the measurements as means, standard deviations, and ranges. Ratios were calculated to determine the relationship between the midpoint of the IP joint flexion creases, the thumb tip, and the proximal margin of the A1 pulley.

RESULTS

Tables 1 and 2 list the measurements. There was a distinct demarcation between the A1 pulley and the variable annular pulley. The variable annular pulley exhibited both transverse (12 specimens) and oblique (8 specimens) configurations, as recognized by others.^{10,11}

The proximal margin of the A1 pulley was located an average of 0.3 mm proximal to the most proximal MCP joint flexion crease. The ratio of measurements from the tip of the thumb to the midpoint of the IP joint flexion creases, and from this point to the proximal margin of the A1 pulley, averaged 1.1:1 (range, 0.8:1–1.3:1).

The RDN passed over the FPL tendon at an oblique angle in a proximal-ulnar to distal-radial direction. The RDN approached the proximal margin of the A1 pulley by a mean distance of 2.7 mm and was located an average of 0.9 mm proximal to a line extended proximally along the radial border of the index finger.

At the level of the A1 pulley, both digital nerves coursed parallel with the tendon sheath. The RDN was

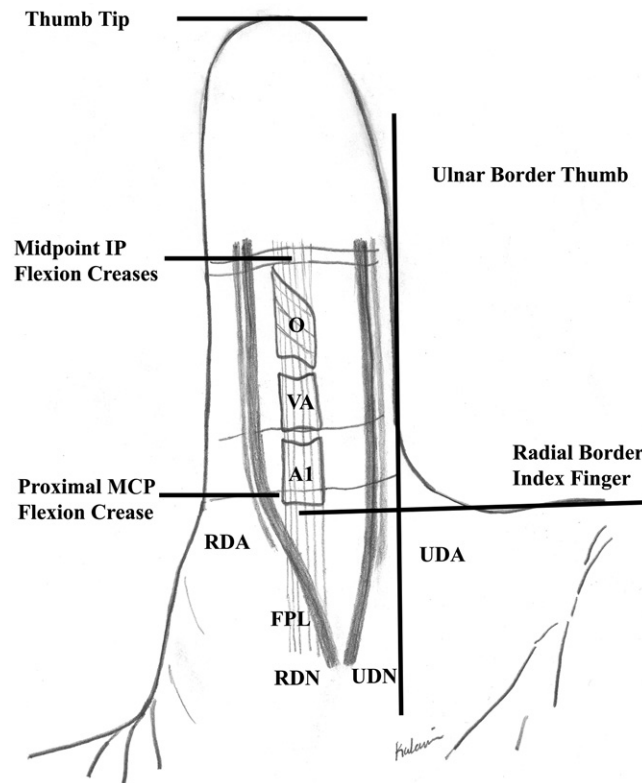


FIGURE 3: Illustration of hand surface landmarks and pertinent anatomic structures. A1, A1 pulley; VA, variable annular pulley; O, oblique pulley.

TABLE 1. Structural Measurements

Structure	Measurement (mm)
A1 pulley (longitudinal width)	6.2 ± 0.9 (4.4–7.8)
A1 pulley (transverse width)	5.7 ± 0.8 (4.4–7.8)
Variable annular pulley (longitudinal width)	T: 5.8 ± 1.7 (3.3–8.8) O: 6.8 ± 2.3 (4.0–9.9)
Oblique pulley (longitudinal width)	9.7 ± 1.8 (7.5–13.8)
Diameter radial digital nerve	2.2 ± 0.4 (1.5–2.8)
Diameter radial digital artery	1.1 ± 0.3 (0.6–1.6)
Diameter ulnar digital nerve	2.6 ± 0.7 (1.4–3.9)
Diameter ulnar digital artery	1.6 ± 0.5 (0.8–2.6)

Data are presented as means, standard deviations, and ranges. T, transverse pulley configuration; O, oblique pulley configuration.

located a mean distance of 0.4 mm and the UDN was located a mean distance of 5.4 mm from the radial and ulnar margins of the A1 pulley, respectively. Both digital arteries were positioned dorsal to the digital nerves, and both nerves were located 1.0 to 4.2 mm from the skin surface at this level. The ranges for all of these measurements are included in Tables 1 and 2.

DISCUSSION

Reports of open and percutaneous techniques in the treatment of trigger thumb have shown generally good outcomes and few adverse sequelae.^{12–15} However, incomplete release of the A1 pulley, excessive release of the tendon sheath distal to the A1 pulley, tendon laceration, and injury to the digital neurovascular structures are recognized and potentially devastating complications of surgery.^{1,3,5,10–12,14,16–24} Corticosteroid injection into the princeps pollicis artery with resultant digital necrosis has also been reported.²⁵

Hazani and Wilhelm⁴ studied the location of the thumb A1 pulley in relation to the MCP joint flexion creases and found that the proximal margin of this pulley was situated 1.0 ± 1.5 mm proximal to the most proximal MCP joint flexion crease. Jongjirasiri⁵ evaluated the dorsal prominence of the first metacarpal head as a landmark for the thumb A1 pulley and localized the proximal margin of the pulley to within 2 mm distal of a perpendicular line passing through the bony protuberance.

Variable numbers of thumb MCP joint flexion creases have been recognized,⁴ and the dorsal prominence of the first metacarpal head can be difficult to

TABLE 2. Relationship Measurements

Relationship	Distance (mm)
Proximal margin A1 pulley to index finger border	5.8 ± 3.7 (0.0–13.5), distal to index finger border
Proximal margin A1 pulley to proximal MCP flexion crease	0.3–1.3 (3.2 proximal to 2.3 distal to MP flexion crease)
Proximal margin A1 pulley to proximal crossing of RDN over FPL tendon	19.7 ± 5.2 (9.5–29.4), proximal to A1 pulley
Proximal margin A1 pulley to distal crossing of RDN over FPL tendon	2.7 ± 3.7 (0.0–12.9), proximal to A1 pulley
Distal crossing of RDN over FPL tendon to midpoint IP flexion creases	37.4 ± 5.1 (30.7–50.3)
Distal crossing of RDN over FPL tendon to index finger border	0.9 ± 2.3 (0.0–9.0), proximal to index finger border
UDN to crossing point of index and thumb borders	0.7 ± 1.0 (0.0–3.9), toward midline
Midpoint IP flexion creases to thumb tip	33.7 ± 3.8 (26.0–39.7)
Midpoint IP flexion creases to proximal margin A1 pulley	32.3 ± 3.2 (25.5–38.1)
Skin surface to RDN	2.9 ± 0.7 (1.4–4.2)
Skin surface to UDN	2.0 ± 0.7 (1.0–3.3)
Radial border of A1 pulley to RDN	0.4 ± 0.6 (0.0–1.8)
Radial border of A1 pulley to RDA	2.5 ± 1.5 (0.0–5.3)
Ulnar border of A1 pulley to UDN	5.4 ± 2.6 (0.0–11.1)
Ulnar border of A1 pulley to UDA	6.0 ± 3.3 (0.0–16.2)
Distal margin A1 pulley to proximal variable annular pulley	3.8 ± 1.4 (0.0–7.1)

Data are presented as means, standard deviations, and ranges.

localize. The proximal border of the A1 pulley was located 0.3 ± 1.3 mm proximal to the most proximal MCP joint flexion crease in our specimens, similar to the findings of Hazani and Wilhelmi.⁴ Relative to a line extended proximally from the radial border of the neutrally aligned index finger, the proximal margin of the A1 pulley was between 0 and 13.5 mm distally. Using the midpoint of the thumb IP joint flexion creases, we measured an average ratio of 1.1:1 in the distances between this point and the thumb tip and the proximal margin of the A1 pulley. An analogous flexion crease ratio has proven effective in localizing the A1 pulley in fingers, eliminating the variability in anthropometric measurements between individuals.^{26,27}

Hand surface landmarks were also useful in localizing the radial and ulnar digital nerves to the thumb. The distal crossing point of the RDN over the FPL tendon was located between 0 and 9 mm proximal to a line drawn along the radial border of the index finger, whereas the distance between the distal crossing point of the RDN over the FPL tendon and the midpoint of the IP joint flexion creases was more variable. The UDN was situated almost immediately below intersecting lines drawn along the radial border of the index finger and the ulnar border of the thumb.

Internal measurements were helpful in defining safe margins for dissection around the A1 pulley. The longitudinal width of the A1 pulley measured 6.2 ± 0.9 mm in our specimens, comparable to values ranging from 4 to 9 mm in other studies.^{4,5,10,11,28} We noted a distinct separation between the distal end of the A1 pulley and the proximal margin of the variable annular pulley, in agreement with Bayat et al.¹⁰ In contrast, a cadaveric study by Schubert et al.¹¹ found occasional fusion of the A1 and variable annular pulleys. Preservation of the variable annular pulley may be necessary to deter tendon bowstringing in the absence of the A1 pulley.^{10,11}

The diameters of the volar digital nerves at the level of the A1 pulley in our specimens measured between 1.4 and 3.9 mm, in agreement with previous reports.^{20,29} The RDN was generally in closer proximity to the A1 pulley than the UDN, similar to the findings of Buldu et al.¹⁸ The depths of the digital nerves from the skin surface varied from 1.0 to 4.2 mm, comparable to the findings of Carrozzella et al.²⁰ and Wallace and Coupland.²⁹ Relative to the digital nerves, the digital arteries were located dorsally and at equivalent or greater distances from the A1 pulleys.

Several limitations of our study may have affected

our findings and conclusions. The number of specimens was relatively small; consequently, all variations in the anatomic arrangements of the A1 pulley and neurovascular structures were unlikely to have been represented.^{30–34} Furthermore, measurements conceivably differed among thumb specimens of different ages and sexes and with different body builds. We did not assess the relationship between small digital nerve branches and the A1 pulley.³² Finally, latex injection and dissection and retraction of soft tissues could have altered the positions of the neurovascular structures and obscured the measurements.

Based on the findings from our study, skin surface landmarks may be helpful in the treatment of trigger thumb. Knowledge of anatomic variability and the relationships between the surface landmarks, the volar neurovascular structures, and the A1 pulley may help to circumvent iatrogenic injuries with injection or surgery.

REFERENCES

- Ryzewicz M, Wolf JM. Trigger digits: principles, management, and complications. *J Hand Surg Am.* 2006;31(1):135–146.
- Saldana MJ. Trigger digits: diagnosis and treatment. *J Am Acad Orthop Surg.* 2001;9(4):246–252.
- Bain GI, Turnbull J, Charles MN, Roth JH, Richards RS. Percutaneous A1 pulley release: a cadaveric study. *J Hand Surg Am.* 1995;20(5):781–784.
- Hazani R EJ, Wilhelmi BJ. Transverse anatomic landmarks for the A1 pulley of the thumb. *Hand.* 2011;6(4):416–419.
- Jongjirasiri Y. The results of percutaneous release of trigger digits by using full handle knife 15 degrees: an anatomical hand surface landmark and clinical study. *J Med Assoc Thai.* 2007;90(7):1348–1355.
- Pope DF, Wolfe SW. Safety and efficacy of percutaneous trigger finger release. *J Hand Surg Am.* 1995;20(2):280–283.
- Sunil TM. Clinical indicators of normal thumb length in adults. *J Hand Surg Am.* 2004;29(3):489–493.
- Gellman H, Botte MJ, Shankwiler J, Gelberman RH. Arterial patterns of the deep and superficial palmar arches. *Clin Orthop Relat Res.* 2001;(383):41–46.
- Hazani R, Whitney RD, Redstone J, Chowdhry S, Wilhelmi BJ. Safe treatment of trigger thumb with longitudinal anatomic landmarks. *Eplasty.* 2010;10. pii:e57.
- Bayat A, Shaaban H, Giakas G, Lees VC. The pulley system of the thumb: anatomic and biomechanical study. *J Hand Surg Am.* 2002;27(4):628–635.
- Schubert MF, Shah VS, Craig CL, Zeller JL. Varied anatomy of the thumb pulley system: implications for successful trigger thumb release. *J Hand Surg Am.* 2012;37(11):2278–2285.
- Blumberg N, Arbel R, Dekel S. Percutaneous release of trigger digits. *J Hand Surg Br.* 2001;26(3):256–257.
- Bruijnzeel H, Neuhaus V, Fostvedt S, Jupiter JB, Mudgal CS, Ring DC. Adverse events of open A1 pulley release for idiopathic trigger finger. *J Hand Surg Am.* 2012;37(8):1650–1656.
- Cebesoy O, K G, Kose KC, Baltaci ET, Isik M. Percutaneous release of the trigger thumb: is it safe, cheap and effective? *Int Orthop (SOCIT).* 2007;31(3):345–349.
- Gilberts ECAM, Beekman WH, Stevens HJPD, Wereldsma JCJ. Prospective randomized trial of open versus percutaneous surgery for trigger digits. *J Hand Surg Am.* 2001;26(3):497–500.
- Will R, Lubahn J. Complications of open trigger finger release. *J Hand Surg Am.* 2010;35(4):594–596.
- Turowski GA, Zdankiewicz PD, Thomson JG. The results of surgical treatment of trigger finger. *J Hand Surg Am.* 1997;22(1):145–149.
- Buldu H, Cepel S, Ki N, Agritmis H. References to avoid complications in releases of the trigger thumb: a cadaveric study. *Acta Orthop Traumatol Turcica.* 2006;40(4):311–314.
- Calleja H, Tanchuling A, Alagar D, Tapia C, Macalalad A. Anatomic outcome of percutaneous release among patients with trigger finger. *J Hand Surg Am.* 2010;35(10):1671–1674.
- Carrozzella J, Stern PJ, Von Kuster LC. Transection of radial digital nerve of the thumb during trigger release. *J Hand Surg Am.* 1989;14(2, Pt 1):198–200.
- Esplin VS, Tencer AF, Hanel DP, Cosio MQ. Restoration of function of the thumb flexor apparatus requires repair of the oblique and one adjacent flexor tendon pulley. *J Orthop Res.* 1996;14(1):152–156.
- Taylor SA, Osei DA, Jain S, Weiland AJ. Digital artery pseudoaneurysm following percutaneous trigger thumb release: a case report. *J Bone Joint Surg Am.* 2012;94(2):e6.
- Thorpe AP. Results of surgery for trigger finger. *J Hand Surg Am.* 1988;13(2):199–201.
- Zissimos AG, Szabo RM, Yinger KE, Sharkey NA. Biomechanics of the thumb flexor pulley system. *J Hand Surg Am.* 1994;19(3):475–479.
- Park J, Dumanian GA. Shower emboli and digital necrosis after a single corticosteroid injection for trigger thumb: case report. *J Hand Surg Am.* 2009;34(2):313–316.
- Fiorini HJ, Santos JB, Hirakawa CK, Sato ES, Faloppa F, Albertoni WM. Anatomical study of the A1 pulley: length and location by means of cutaneous landmarks on the palmar surface. *J Hand Surg Am.* 2011;36(3):464–468.
- Wilhelmi BJ, Snyder N IV, Verbese JE, Ganchi PA, Lee WP. Trigger finger release with hand surface landmark ratios: an anatomic and clinical study. *Plast Reconstr Surg.* 2001;108(4):908–915.
- Doyle JR, Blythe WF. Anatomy of the flexor tendon sheath and pulleys of the thumb. *J Hand Surg Am.* 1977;2(2):149–151.
- Wallace WA, Coupland RE. Variations in the nerves of the thumb and index finger. *J Bone Joint Surg Br.* 1975;57(4):491–494.
- Earley MJ. The arterial supply of the thumb, first web and index finger and its surgical application. *J Hand Surg Am.* 1986;11(2):163–174.
- Falconer D, Spinner M. Anatomic variations in the motor and sensory supply of the thumb. *Clin Orthop Relat Res.* 1985;(195):83–96.
- Hirasawa Y, Sakakida K, Tokioka T, Ohta Y. An investigation of the digital nerves of the thumb. *Clin Orthop Relat Res.* 1985;(198):191–196.
- Parks BJ, Arbelaez J, Horner RL. Medical and surgical importance of the arterial blood supply of the thumb. *J Hand Surg Am.* 1978;3(4):383–385.
- Jolley BJ, Stern PJ, Starling T. Patterns of median nerve sensory innervation to the thumb and index finger: an anatomic study. *J Hand Surg Am.* 1997;22(2):228–231.